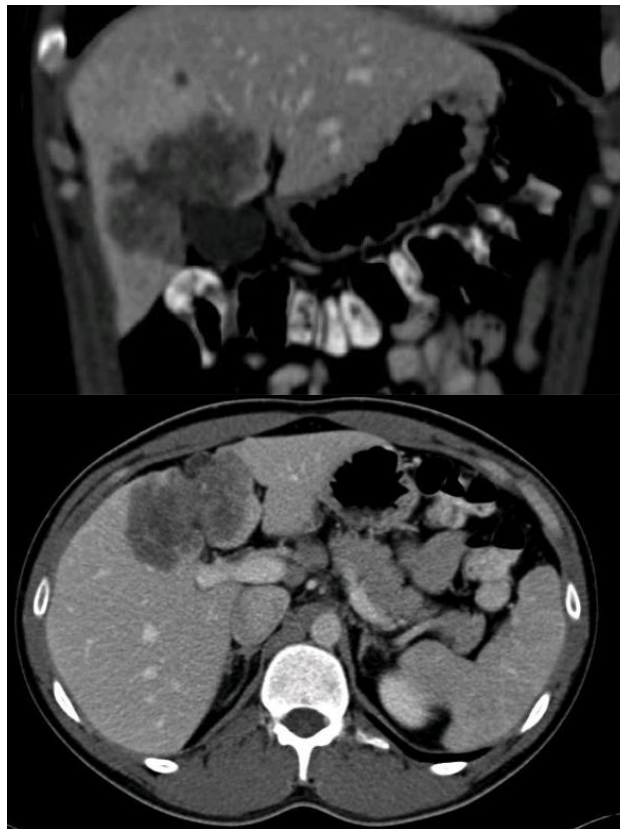


Case report

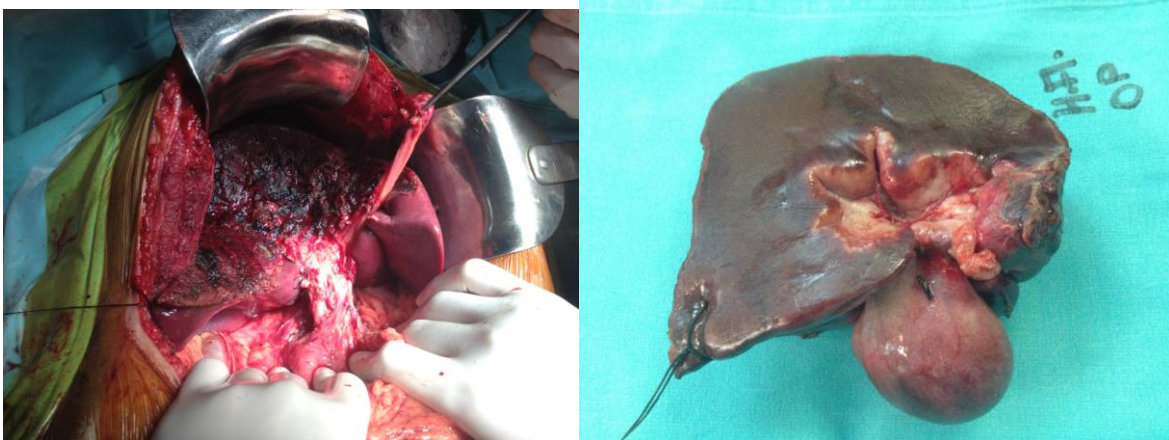
A 29 -year old- male patient without any medical history was incidentally diagnosed with a giant hepatic mass during laparoscopic appendectomy (intra-operative biopsy revealed: cholangiocarcinoma).

Blood test showed normal liver function with elevation of Ca19-9 (>264 ng/mL, normal value= <35 ng/ml).

A thoracic and abdominal CT scan showed a heterogeneous mass of 8 x 5 cm in segment IVa-V with satellite nodule of 1 cm (Figure 1-2) and absence of extra-hepatic disease.



Surgical treatment: A central hepatectomy en-block with gallbladder was performed (Figure 3) associated with hepatic hilus lymph-adenectomy.



Pathological specimen: Moderate differentiated intra-hepatic cholangiocarcinoma of 6,7 x 4,5 with a satellite nodule of 1 cm. No lymph node metastases (0/2). Negative surgical margin.

Stage: pT2b N0 M0.

Key question: Should we perform adjuvant therapy on this patient?

Note: At our tumor conference, our oncologists favor chemotherapy therapy based on two potential risk factors: the presence of a satellite nodule (could be considered as a metastases), and a long-life expectancy (very young patient)

Answer: Yes